Left Atrial Enlargement and Systolic Failure Is Related to Chymase Activation in Patients with Mitral Regurgitation and Preserved Left Ventricular Ejection Fraction

Brittany Butts, Pamela Cox Powell, Betty Pat, Ryan Wong, Silvio Litovsky, Himanshu Gupta, Steven G Lloyd, Thomas S Denney, Xiaoxia Zhang, Nouha Salibi, Inmaculada Aban, James Collawn, James E Davies, and Louis J Dell'Italia
University of Alabama at Birmingham, Birmingham Department of Veterans Affairs Medical Center, and Auburn University

ACC.18 67th Annual Scientific Session & Expo

1168-398

Introduction

- In the volume overloaded left atrium (LA) of patients with isolated mitral regurgitation (MR), LA size has demonstrated prognostic importance in isolated MR even in patients with LVEF > 60%.
- LA from patients with MR have extensive atrial cell myolysis, matrix metalloproteinase (MMP) activation, increased oxidative stress, lipofuscin accumulation, and mitochondrial damage.
- Chymase activity is increased in the left ventricle (LV) in multiple animal models of volume overload.
- Chymase has direct extracellular protease actions but has recently been identified within cardiomyocytes.

Purpose

The purpose of this study is to determine whether LA ultrastructural damage and chymase expression are associated with LA dilatation and contractile dysfunction in patients with isolated MR and preserved LVEF using serial short axis magnetic resonance imaging covering the whole heart for LA volume calculation that is independent of geometric assumptions.

Methods

- Serial short axis MRI was acquired of the entire heart in 11 normal volunteers and 16 patients with isolated MR to calculate LA and LV volumes.
- LA appendage biopsies were collected at the time of mitral valve surgery.
- Degenerative mitral valve disease was documented by echocardiographic evidence of thickening and prolapse of the mitral valve and by the surgeon's description at operation.
- Control subjects did not have a history of cardiovascular disease or smoking, and were not taking any type of cardiovascular medication.
- Tissue analysis included transmission electron microscopy (TEM), in-situ hybridization, and immunohistochemistry (IHC).

Study Sample

	Normal Control (n=11)	MR (n=16)	p-value
Age (years)	60 ± 6	61 ± 12	0.7
Gender			
Male	6 (55%)	11 (69%)	0.5
Female	5(45%)	5 (31%)	
LVEF (%)	62 ± 4	60 ± 8	0.4

UAB SCHOOL OF MEDICINE
Knowledge that will change your world

Results

Magnetic Resonance Imaging

MR LV end diastolic volume was increased nearly 2-fold as compared to normal controls (204 ± 69 vs 106 ± 17, respectively, p=.001). LA volume was increased while LA total emptying fraction was decreased below normal (Figures 1 and 2).

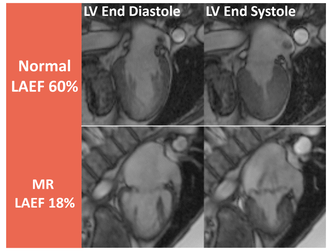

Figure 1. MRI images of a normal volunteer and MR patient at end diastole and end systole.

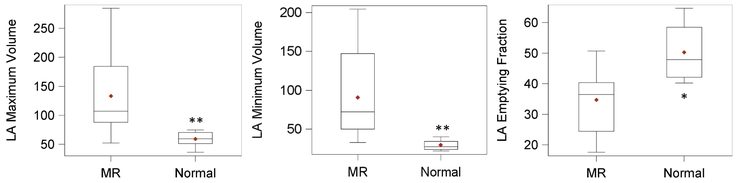

Figure 2. Box plots demonstrating the significant increase in LA maximum and minimum volume and decrease in LA emptying fraction in age-matched normal volunteers vs MR patients.
*p=.003 **p≤.001

Chymase Within LA Myocytes

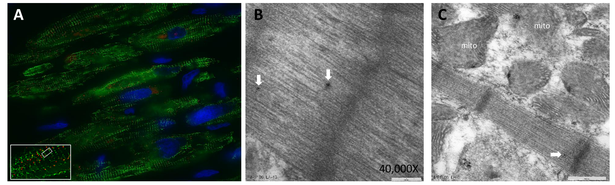

Figure 3. IHC (**A**) of LA from patient with isolated MR demonstrating chymase (red) within LA myocytes and desmin (green) breakdown. 100X insert demonstrates area of chymase (red dots) depicted in TEM immunogold image (**B**) demonstrating chymase (black dots) associated with myofibrils and (**C**) within mitochondria.

Figure 4. Local chymase infiltration of cardiomyocyte as depicted in IHC and in situ chymotryptic activity documents presence and activity of chymase with the cardiomyocte of MR LA.

IHC at 100x demonstrates degranulating mast cell in large white box in lower right with chymase (red) granules within adjacent cardiomyocytes defined by desmin (green).

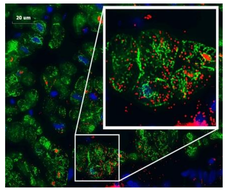

In situ chymotryptic activity in LA of patient with isolated MR documented by intense blue staining in mast cell and within cardiomyocyte in cross section (**A,B**) and longitudinal section (**C,D**) that is prevented by pretreatment of tissue with chymase inhibitor (Teijin compound TEI-F00806) (**B,D**).

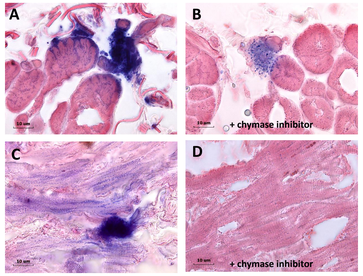

LA Myocardial Ultrastructure

Figure 5. Hematoxylin and eosin stain (left panels) demonstrate diffuse empty areas representing myolysis (arrows) and myofibrillar degeneration. TEM images of the same patients (middle and right panels) show replacement by glycogen accumulation and collections of small, disorganized, and multi-shaped mitochondria with sparsely packed cristae. There are extensive non-membrane bound vacuoles, lipid droplets, and lipofuscin.

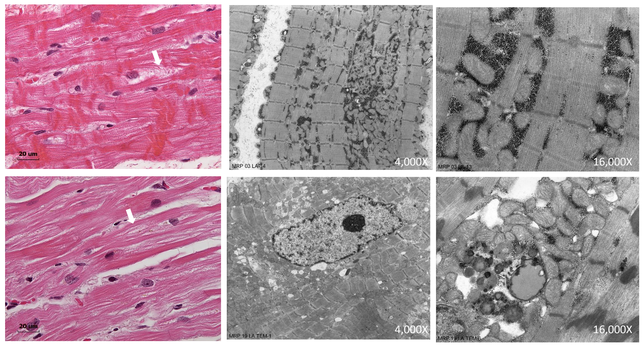

Top TEM: (62 year old white male, LAEDV 88 ml, LAEF 51%) multiple areas of myofibrillar loss replaced by glycogen accumulation (dark black dots) and thickening of the z-discs.
Bottom TEM: (59 year old black male, LAEDV 89 ml, LAEF 40%) multiple areas of sarcomere distortion defined by variable sarcomere lengths, myofibrillar breakdown, lipid droplets and electron dense particles of lipofuscin.

Conclusions and Clinical Implications

- In isolated MR with LVEF > 60%, LA size is markedly increased with systolic dysfunction that is associated with extensive LA myolysis, cytoskeletal (desmin) breakdown, and intracellular chymase activation.
- This study identifies a potential novel intracellular chymase-mediated degradation of cardiomyocyte structural proteins and severe LA dysfunction in isolated MR.

The MR LA ultrastructural changes are similar to the MR LV[1] but are associated with systolic dysfunction in patients with well preserved LVEF. In view of the known prognosis of LA size alone, this study raises the intriguing question whether MRI-derived LA volumes and function may be a more reliable indicator for mitral valve surgery in isolated MR.

1.Ahmed MI, Guichard JL, Soorappan RN, et al. Disruption of desmin-mitochondrial architecture in patients with regurgitant mitral valves and preserved ventricular function. *J Thorac Cardiovasc Surg.* 2016;152(4):1059-1070.e1052.

Funding

NHLBI and Specialized Centers of Clinically Oriented Research grant P50HL077100 (LJD) in cardiac dysfunction, Department of Veteran Affairs Merit Review (Grant 1CX000993 to LJD), and NIH Grant P01HL051952 (LJD). Effort for BB was supported by NIH grant F32NR017322.